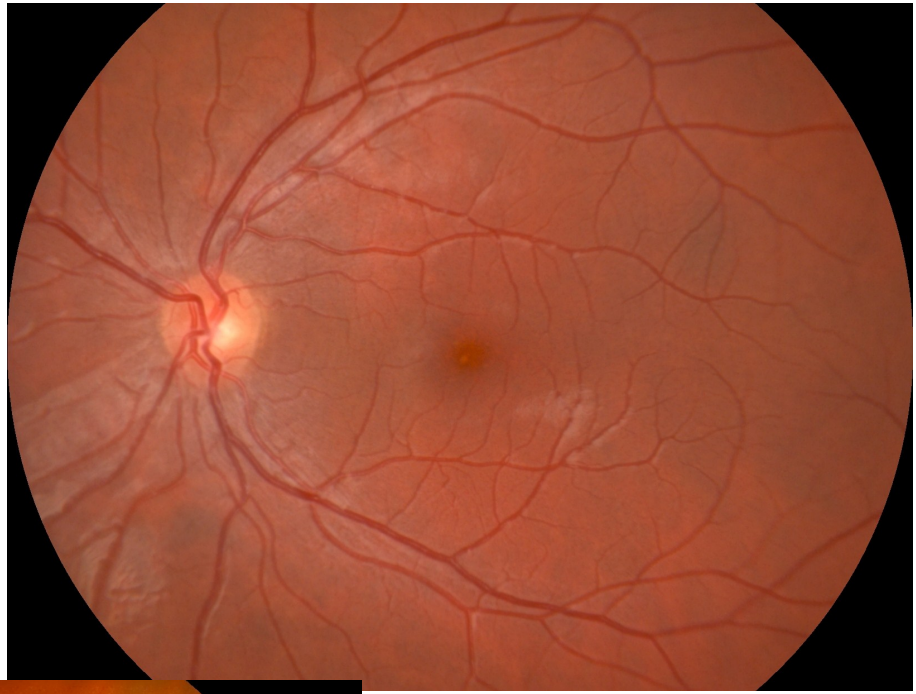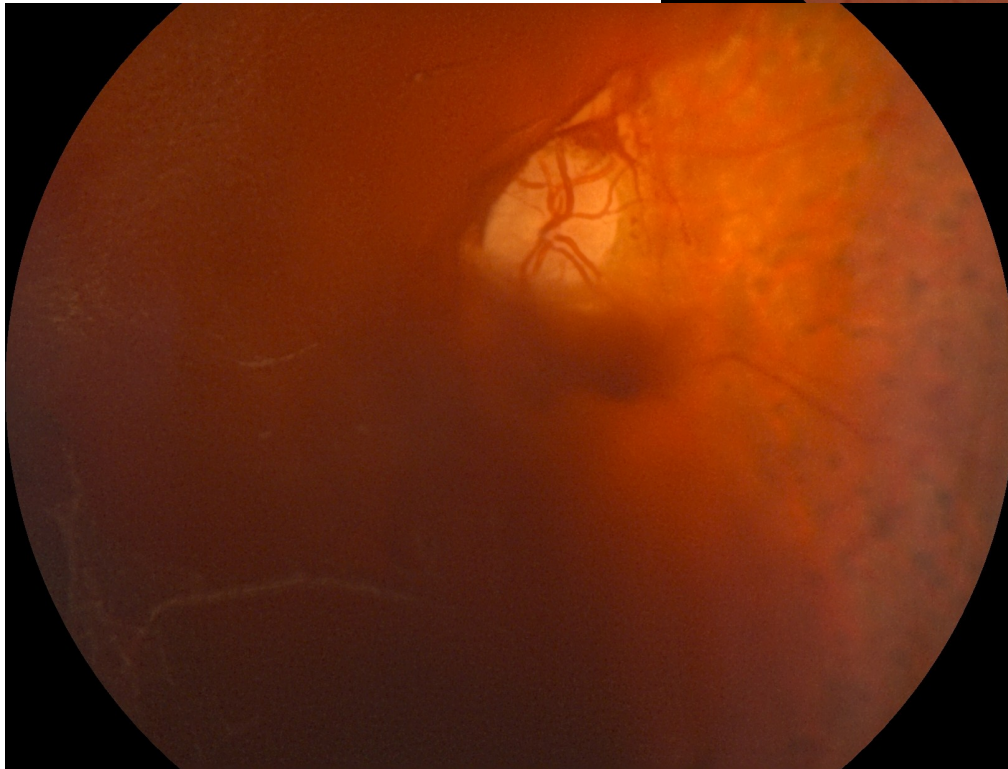


Mild AMD type macular disturbance in a 30 year old



A Sudden onset
total temporal
retinal detachment



The retinal detach-
ment was the only
photo taken through
a dilated pupil. The
retinal nevus patient
had mild cataract

